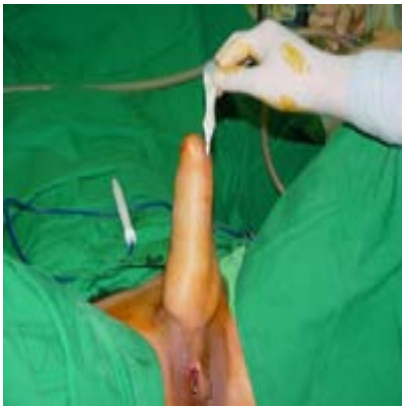
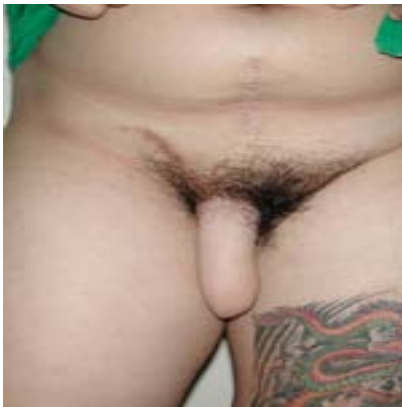
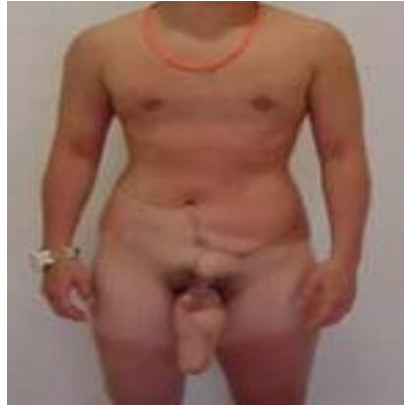
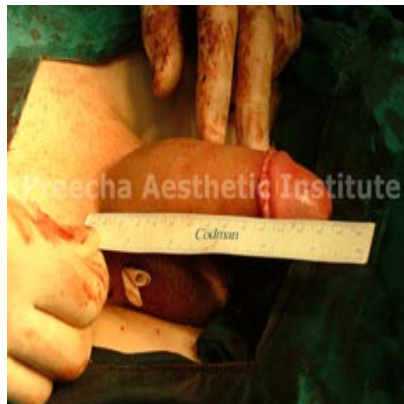
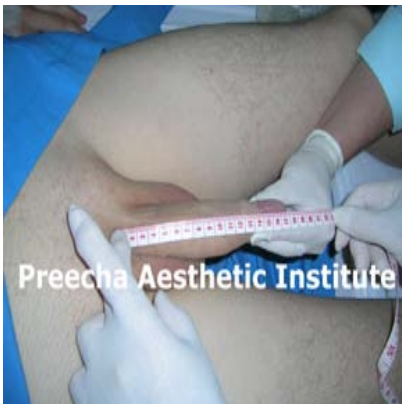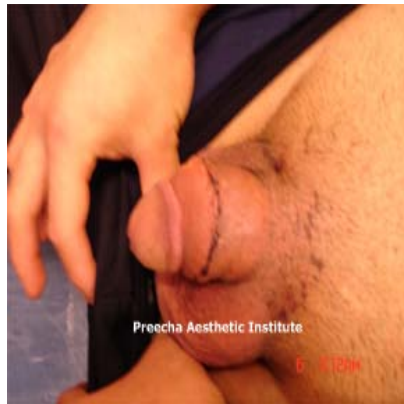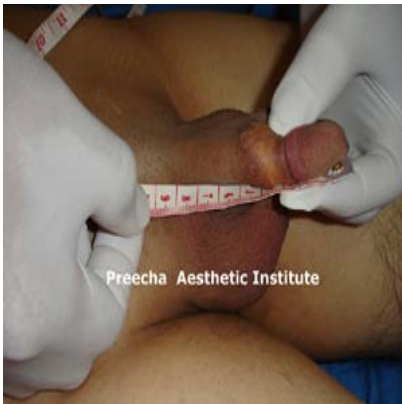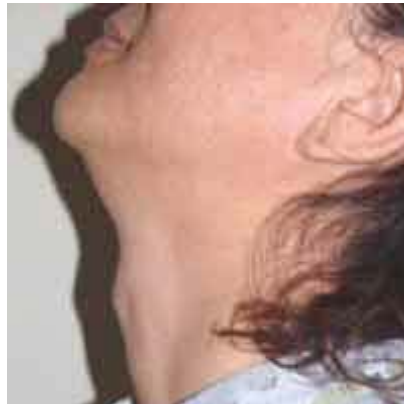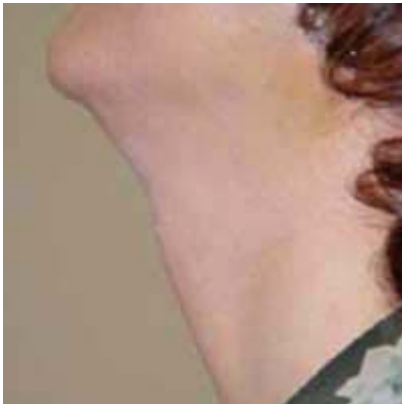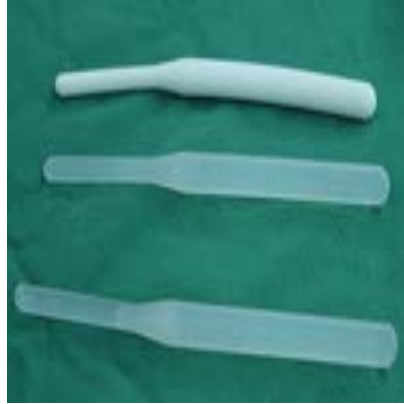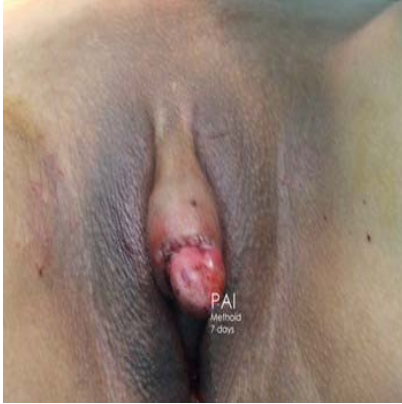Photographic

Examples

Female to Male Procedures:

Metoidioplasty: [Example #2](#) | [Example #3](#) | [Example #4](#) |

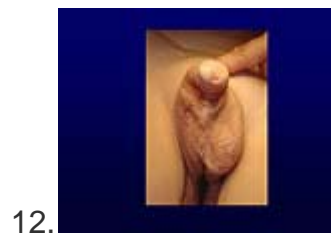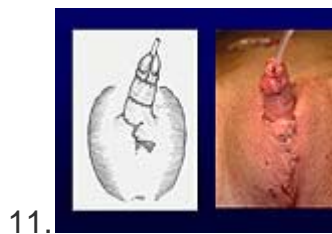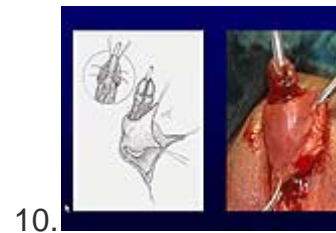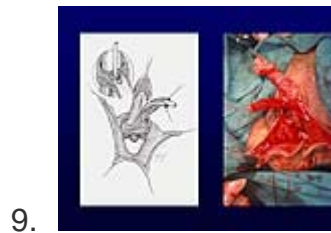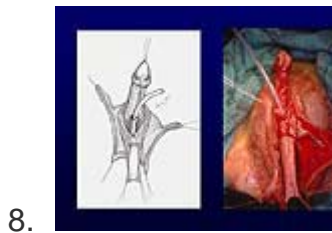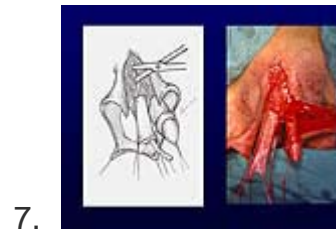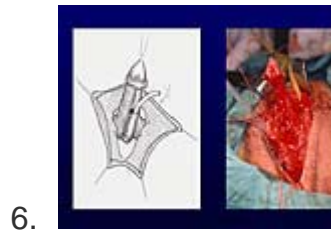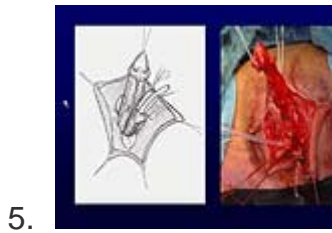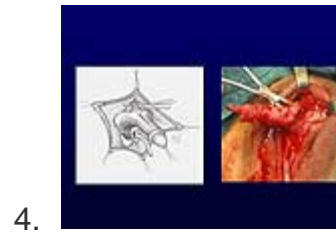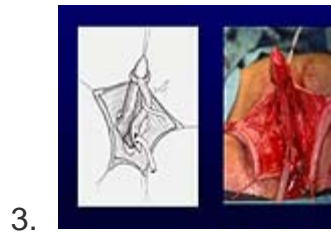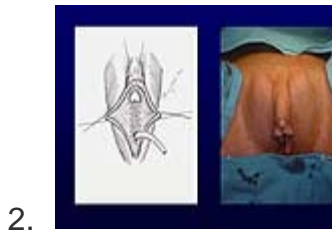Complete process: [Example #5](#) | [Example #6](#) | [Example #7](#)

Testicular Implant: [Example #8](#) | [Example #9](#) **Dr. Harold Reed**

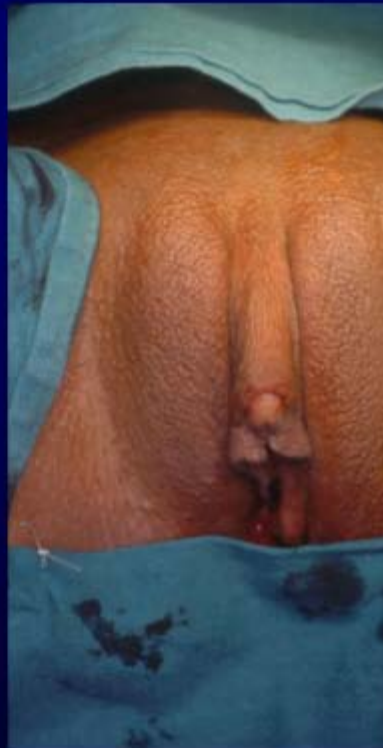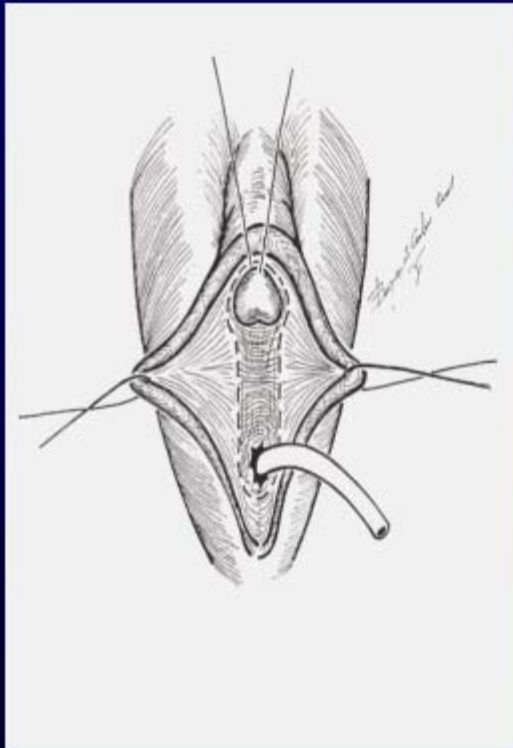
1. **Metoidioplasty**

\*

**Example #5 - 5/1 through 5/11**

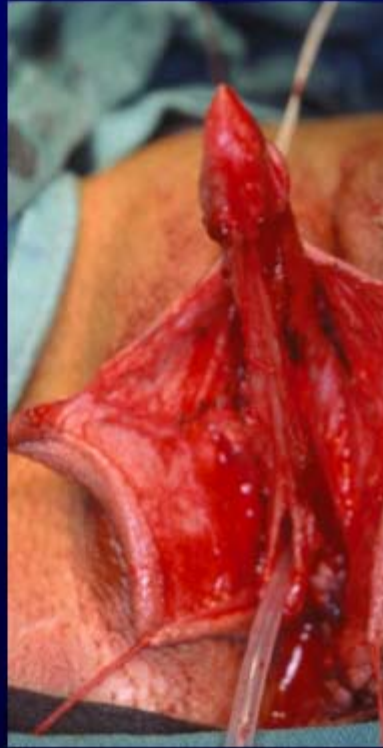
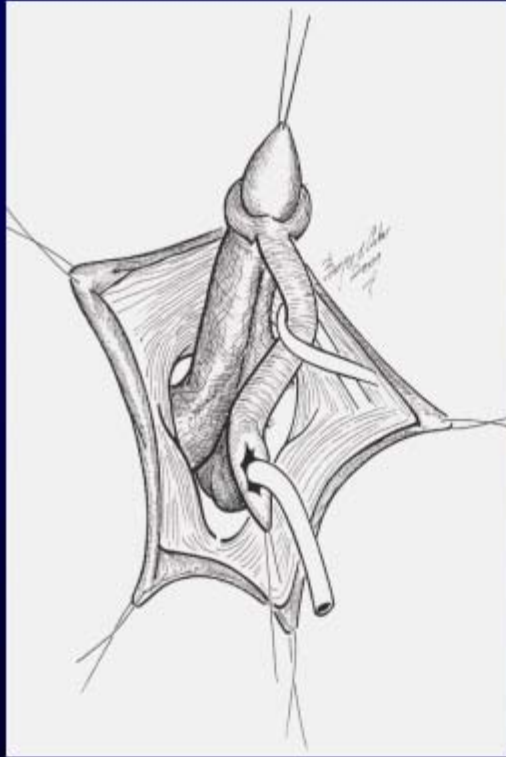
13.



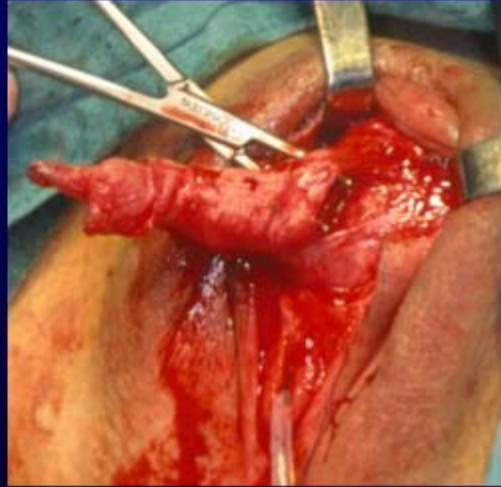
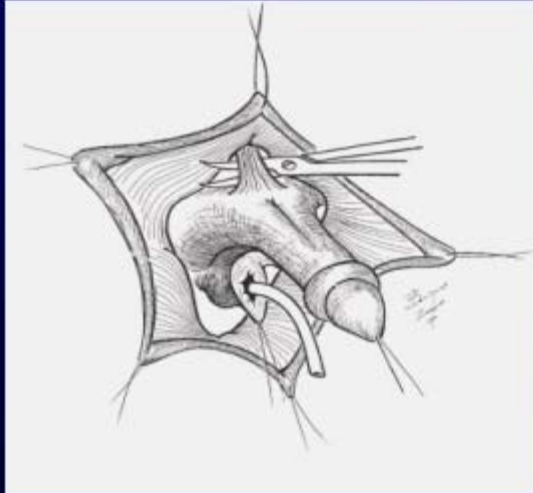
14.

15.

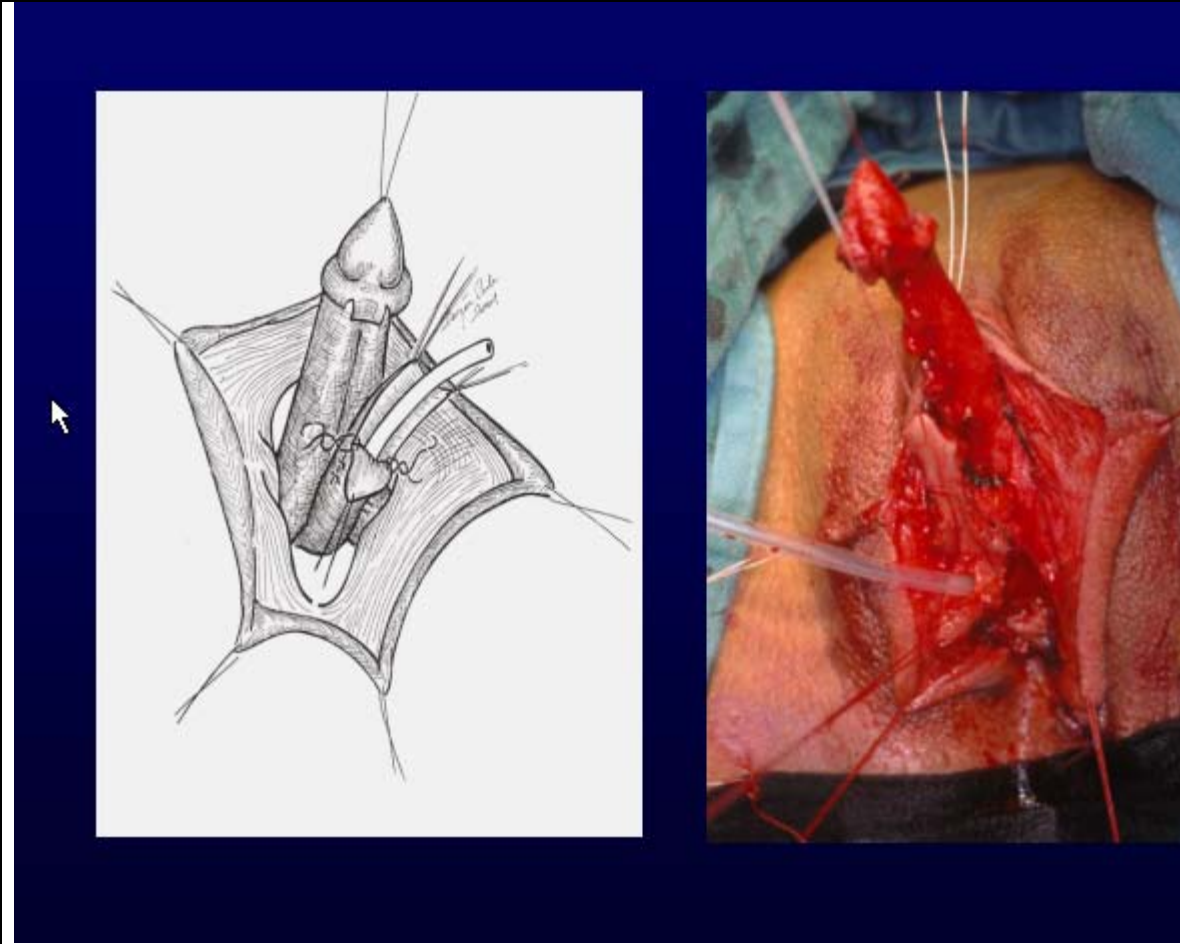


16.

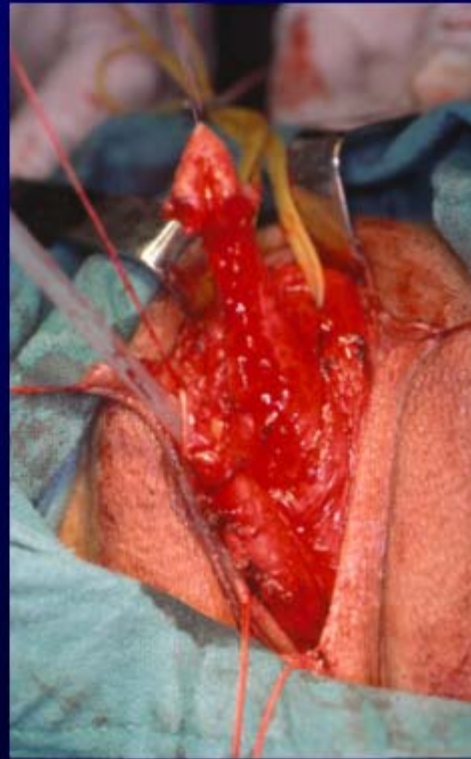
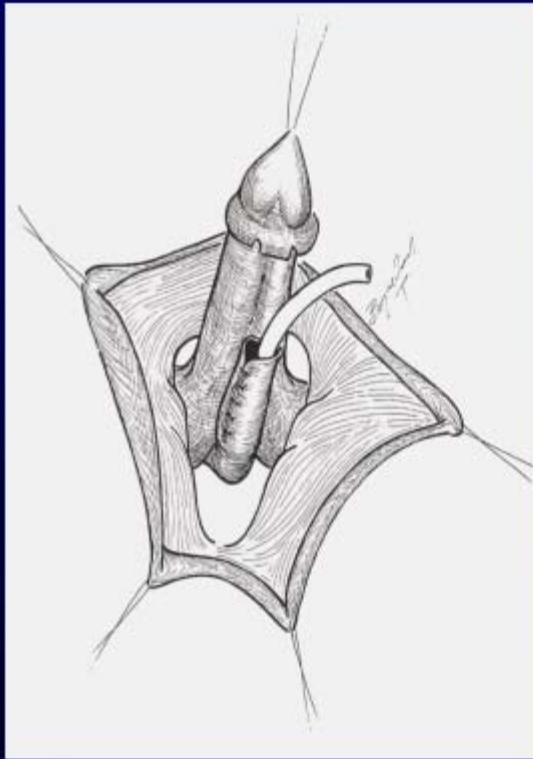17.



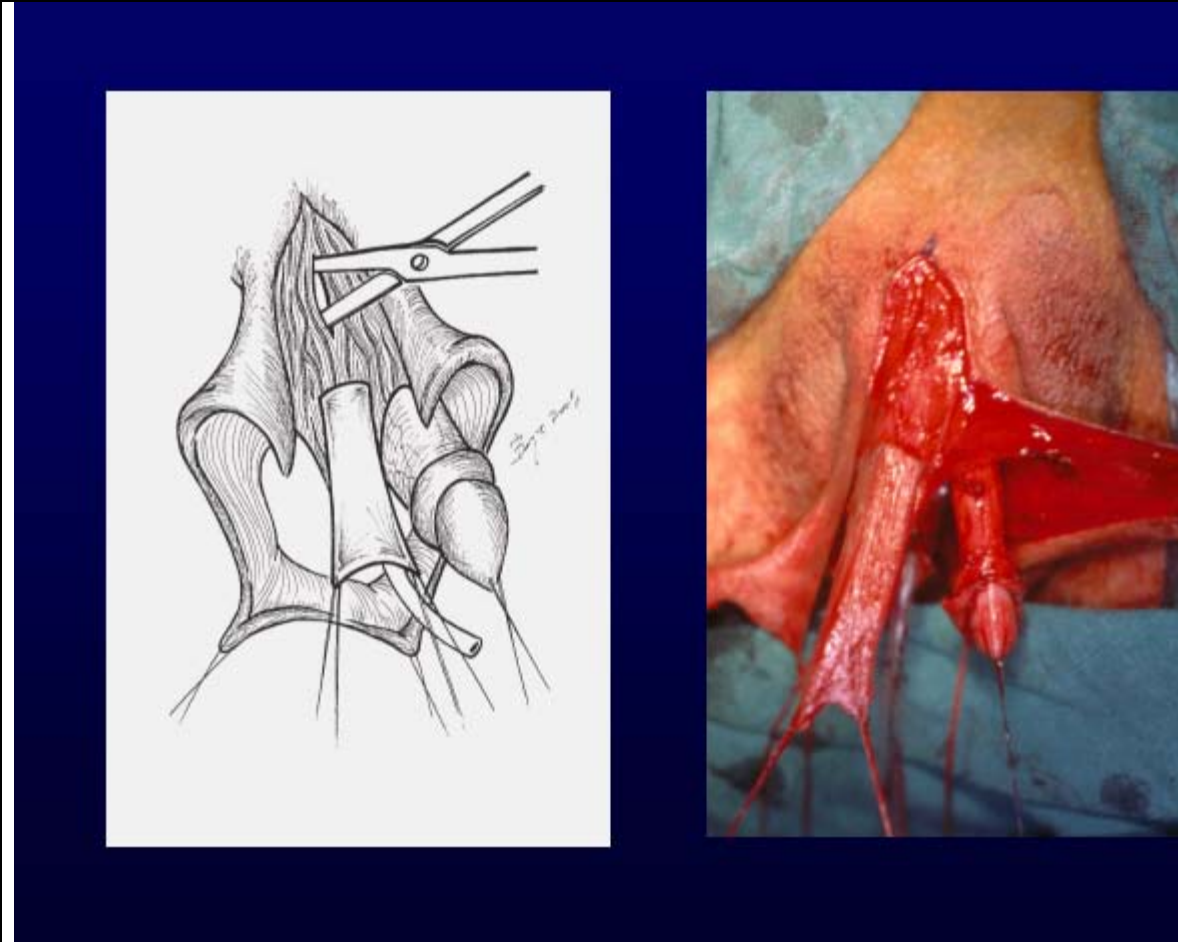
18.



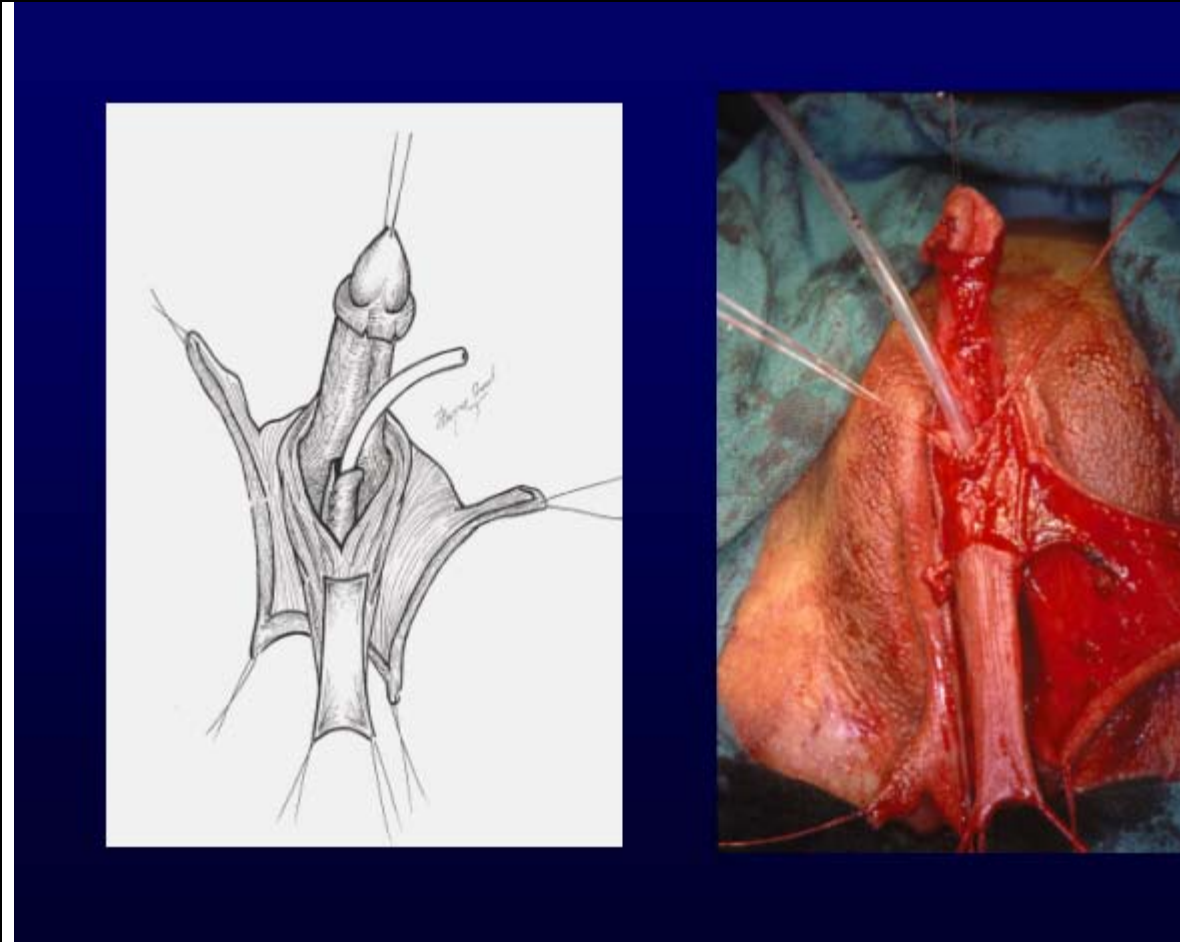
19.



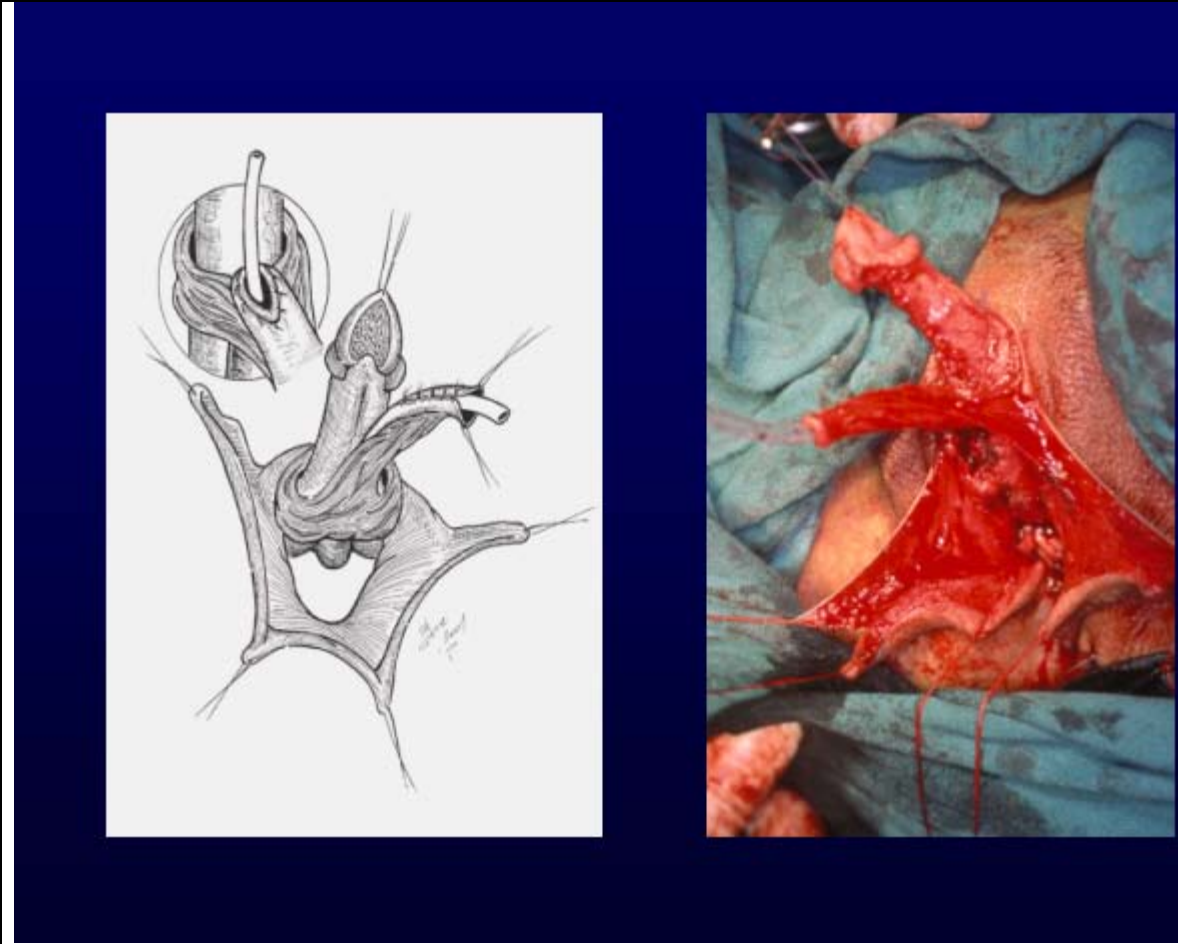
20.



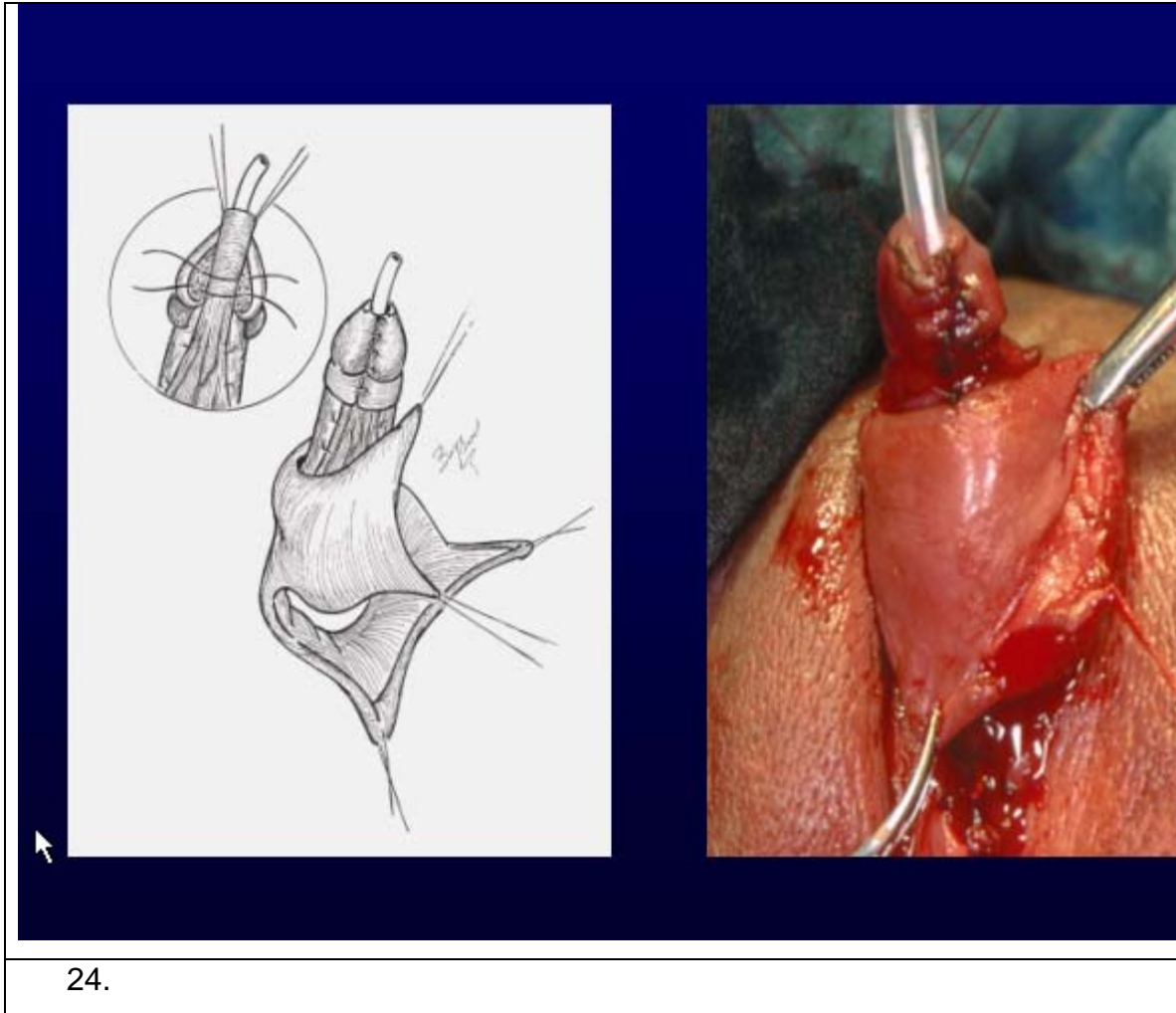
21.



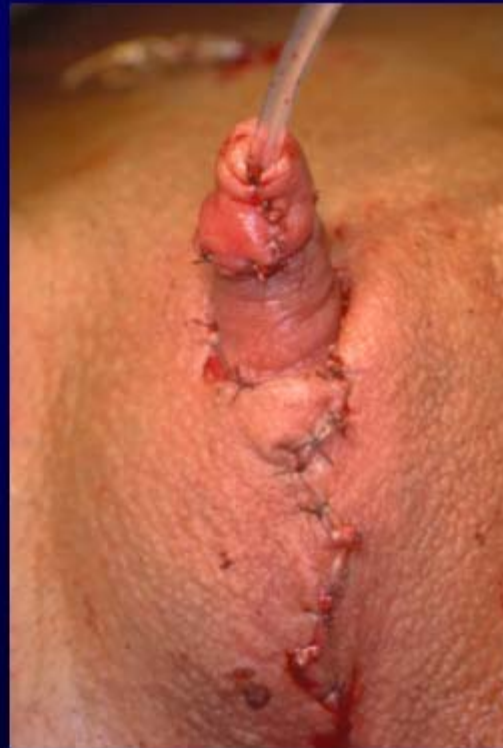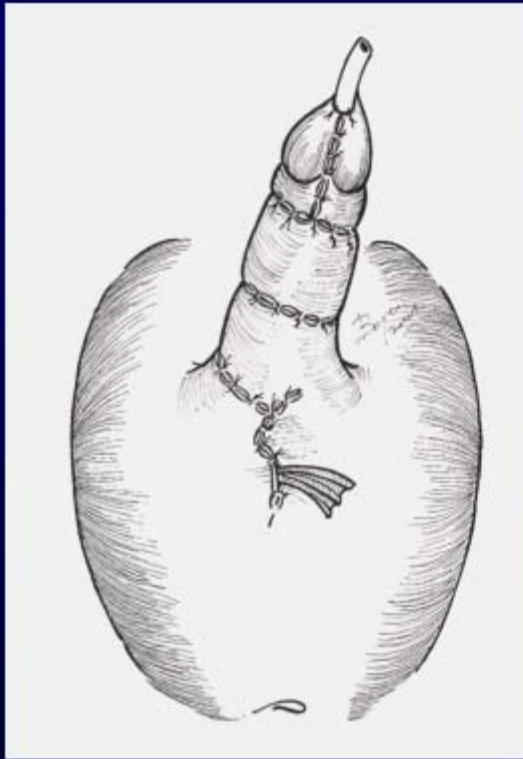
22.



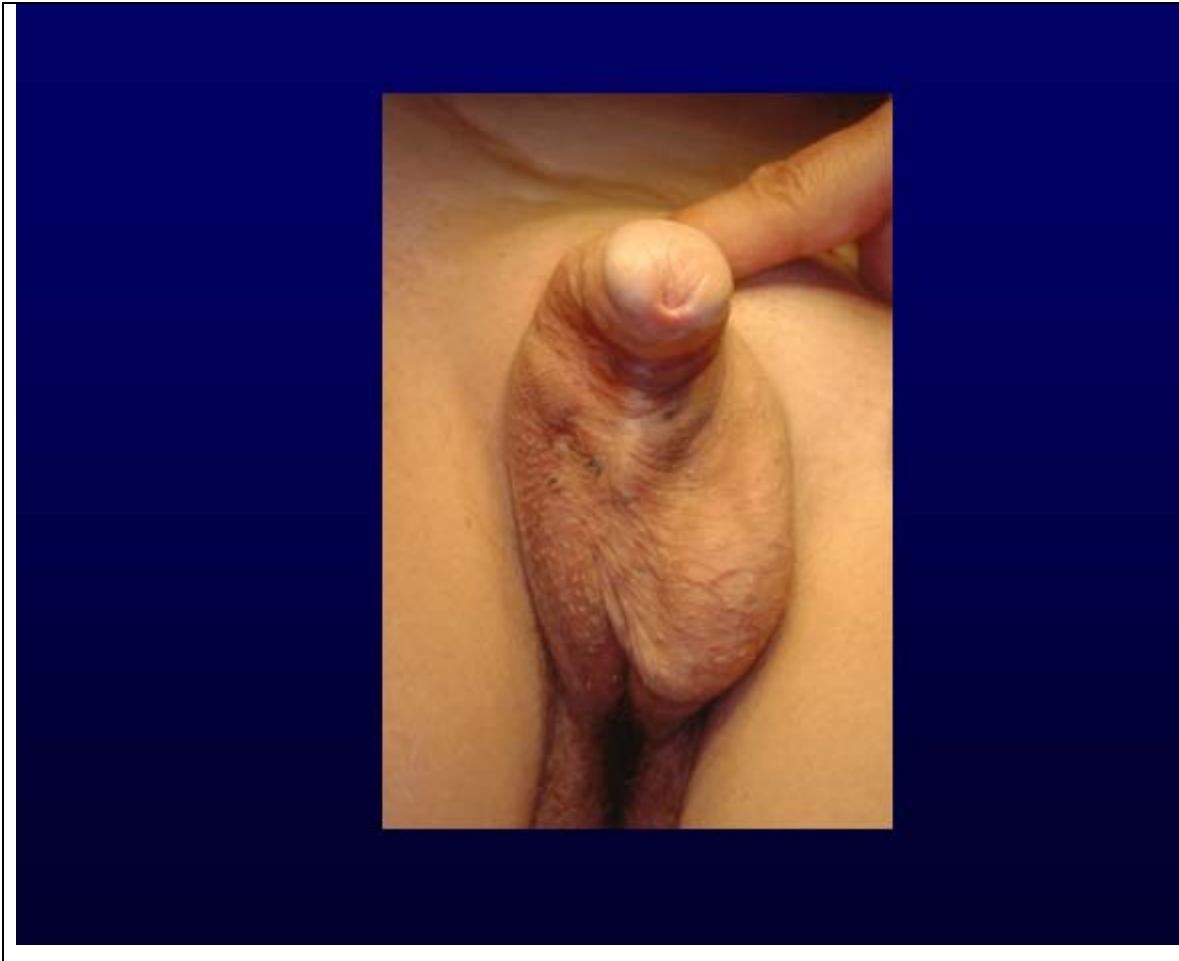23.



24.



25.



**Metoidioplasty**

**Example #6 - 6/1 through 6/**

Surgery date for urethral extension without testis implants, September 19, 2005, photos taken on October 7, 2005. Some pubic fat obscures length. Patient needs to lose 35 pounds. First time

voided, out came 500 cc (about 1/2 quart) with huge stream and excellent trajectory.

6/1



6/2

6/3

[Top](#)

## Metoidioplasty

**Example #7 - 7/1 through 7/1**

Another metoidioplasty patient status post urethral extension and testicular implants. Excellent glans formation and manly shaft.

7/1



7/2



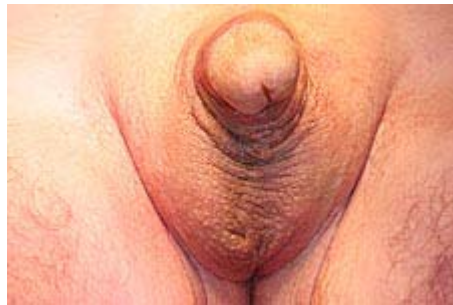7/3



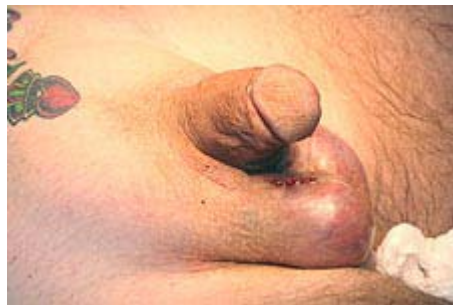[Top](#)

**Testicular Implant on Genetic Male**  
**Example #8 - 8/1 and 8/2**

8/1 Preop: small bilaterally atrophied testes



8/2 Post-op: normal gonadal contours

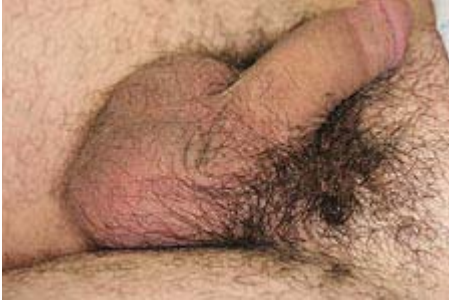

[Top](#)

**Testicular Implant on Genetic Male**  
**Example #9 - 9/1 and 9/2**

Two post op views

9/1



9/2

